




A Squamous



B Cuboidal

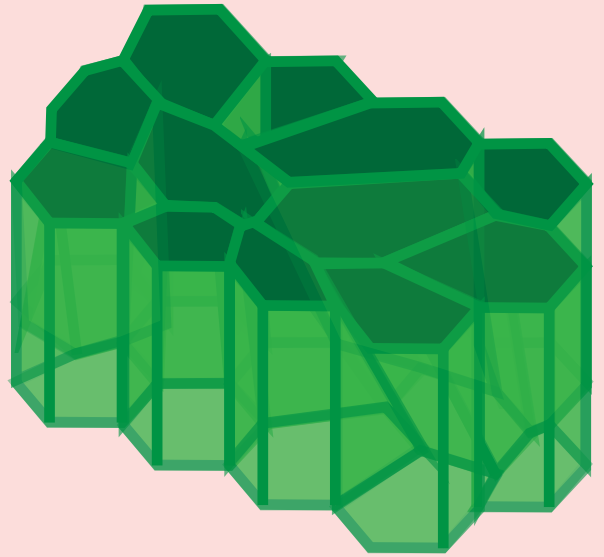


C Columnar




Simple Epithelia

D Pseduo-stratified



E Stratified



Stratified Epithelia